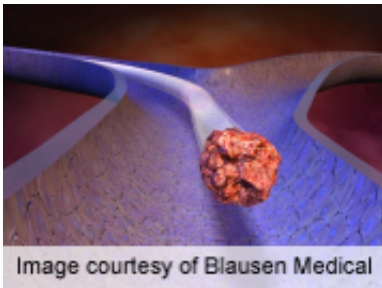


Post-spinal surgery ultrasound aids VTE management

May 16 2014



Perioperative ultrasonography is important for proper management of venous thromboembolism, according to a study published in the May 1 issue of *Spine*.

(HealthDay)—Perioperative ultrasonography is important for proper management of venous thromboembolism (VTE), according to a study published in the May 1 issue of *Spine*.

Koji Akeda, M.D., Ph.D., from the Mie University Graduate School of Medicine in Japan, and colleagues conducted prospective follow-up on 209 [patients](#) undergoing spinal surgery (121 males, 88 females; average age, 64 years) who had ultrasonographic assessments of both legs before and after surgery. For primary VTE prophylaxis, a pneumatic sequential compression device and standard compression stockings were used. Pharmacological agents were not used for VTE prophylaxis unless a distal type [deep venous thrombosis](#) (DVT) was found preoperatively.

The researchers found that 23 patients (11.0 percent) showed VTE in the spinal surgery perioperative period. Before surgery, nine patients (4.3 percent) had VTE (pulmonary embolism [PE] with proximal DVT, one; distal DVT, eight). New-onset VTE developed in 14 patients (6.7 percent; two PE with proximal DVT; 12 distal DVT) after spinal surgery. Two patients developed new-onset PE with proximal DVT after surgery. DVT disappeared (based on follow-up ultrasonography) completely in 85 percent of patients with a distal type DVT (17 of 20).

"DVT assessment using ultrasonography is important for proper management of VTE during the perioperative period of [spinal surgery](#), especially for high-risk patients, such as those with advanced age or neurological deficit," the authors write.

More information: [Abstract](#)
[Full Text \(subscription or payment may be required\)](#)

Copyright © 2014 [HealthDay](#). All rights reserved.

Citation: Post-spinal surgery ultrasound aids VTE management (2014, May 16) retrieved 20 November 2023 from
<https://medicalxpress.com/news/2014-05-post-spinal-surgery-ultrasound-aids-vte.html>

<p>This document is subject to copyright. Apart from any fair dealing for the purpose of private study or research, no part may be reproduced without the written permission. The content is provided for information purposes only.</p>
