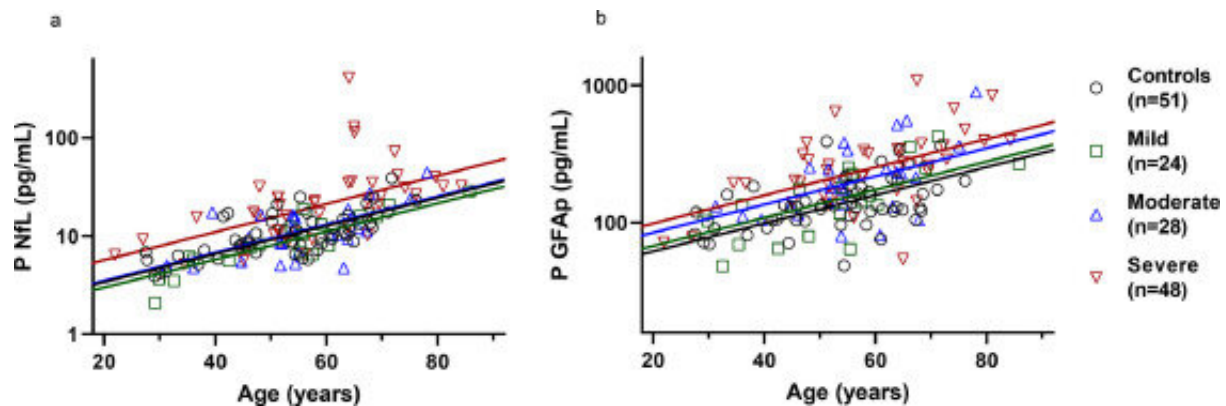


No signs of brain injury post-acute COVID-19

August 5 2021



Plasma concentrations of NfL (a) and GFAP (b) shown in acute phase in patients with mild, moderate, and severe disease, and controls (age on x-axis). Patients with severe disease show higher concentrations of plasma NfL than other groups (p

In a recent study from University of Gothenburg, it has been shown that all participants achieve normalization of CNS injury biomarkers, regardless of previous disease severity or persistent neurological symptoms. Indicating that post-COVID-19 neurological sequelae are not due to active brain injury.

Central nervous system involvement and signs of brain injury have been described since the beginning of the SARS-CoV-2 pandemic. A previous study from the same group showed that hospitalized patients receiving oxygen therapy or ICU care often had signs of brain damage by measuring blood-based biomarker of brain injury.

In addition, in recent months it has been increasingly evident that after the acute

phase of COVID-19, many patients still suffer from persisting neurologic disability. This often includes lethargy, fatigue, or impaired cognitive function. This consequence is now termed post COVID condition.

The mechanism behind how COVID-19 causes persisting neurological symptoms is still not fully understood. In a follow-up study, the researchers aimed to investigate the longitudinal trajectories of the same plasma biomarkers in patients who have recovered from COVID-19, with and without persisting neurological symptoms.

Normalization of markers

The study presented in *EBioMedicine*, recruited 100 COVID-19 patients from the Sahlgrenska University Hospital in Gothenburg, Sweden. The study population was divided into groups according to [disease](#) severity; mild, moderate, and severe COVID-19. Blood samples were collected at an interval of acute phase of the disease, 3- and 6-months post-infection. At the acute phase, patients who required hospitalization and were receiving oxygen therapy or mechanical ventilation showed an increase of NfL (neurofilament light chain protein), a biomarker that increases with neuronal injury, and GFAP (glial fibrillary acidic protein), a biomarker that indicates astrocytic injury or overactivation. At follow-up, all biomarkers returned to their normal baseline values.

In addition, at three and six months clinical follow-up, 50 patients out of the 100 recruited individuals reported one or more neurological symptoms, the most common symptoms were fatigue, "brain-fog," and cognitive impairment, such as memory loss and lack of concentration. Remarkably, there were no difference in frequency of any symptoms among the disease severity groups.

Further research important

"The findings in this study puts an emphasis on the importance of further research that needs to validate the scale of persisting neurological symptoms and recovery, but also to investigate the true cause of this condition. This is of high importance from a scientific and public health point of view in search for better care of this patient group" says the first author Nelly Kanberg, Ph.D. student at

the Infectious Disease at Sahlgrenska Academy, University of Gothenburg and resident medical doctor at the Department of Infectious Disease, Sahlgrenska University Hospital.

Magnus Gisslén, Professor of Infectious Diseases at the Sahlgrenska Academy and chief physician at the Department of Infectious Diseases, Sahlgrenska University Hospital, leads the Academy's clinical research on COVID-19. The results of this study are, in his view, of great importance and encouraging for patients with long-lasting symptoms after COVID-19.

"Neurological complications are common in COVID-19 and can in some patients continue several months after the acute phase. It is reassuring that elevated concentrations of brain-injury markers return to normal 3-6 months after the acute phase of COVID-19 indicating that no continuous brain damage is present and that there is a good chance for recovery also in patients with remaining post-acute neurologic and cognitive symptoms," Gisslén says.

More information: Nelly Kanberg et al, Neurochemical signs of astrocytic and neuronal injury in acute COVID-19 normalizes during long-term follow-up, *EBioMedicine* (2021). [DOI: 10.1016/j.ebiom.2021.103512](https://doi.org/10.1016/j.ebiom.2021.103512)

Provided by University of Gothenburg

Citation: No signs of brain injury post-acute COVID-19 (2021, August 5) retrieved 20 July 2023 from <https://medicalxpress.com/news/2021-08-brain-injury-post-acute-covid-.html>

| |
|--|
| <p>This document is subject to copyright. Apart from any fair dealing for the purpose of private study or research, no part may be reproduced without the written permission. The content is provided for information purposes only.</p> |
|--|