
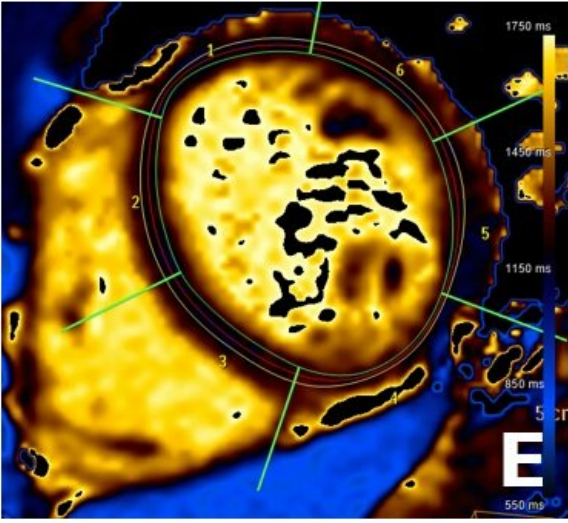
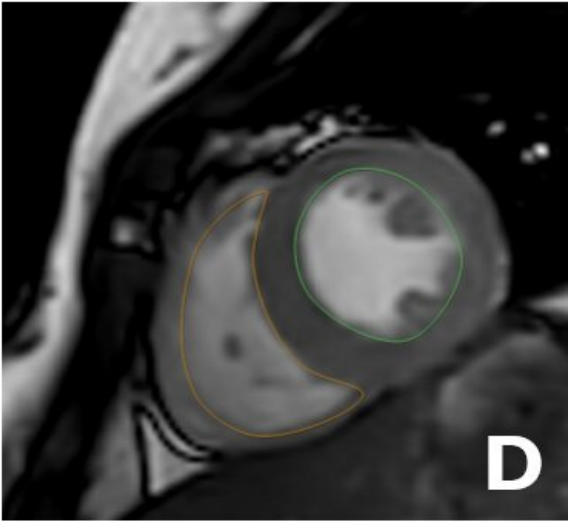
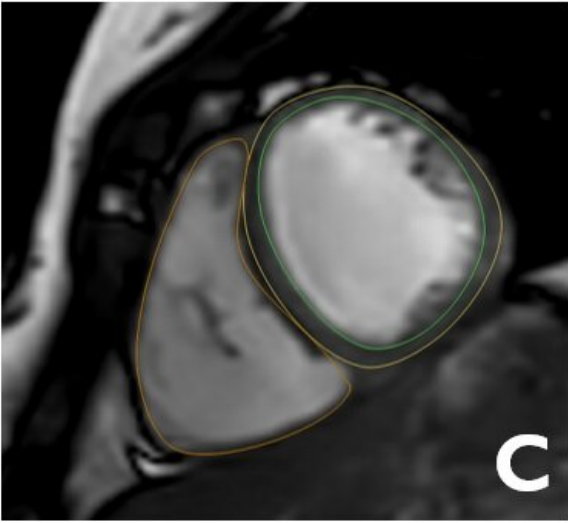
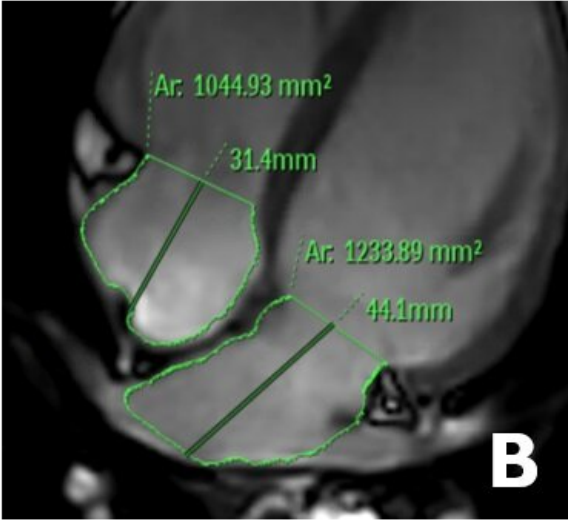
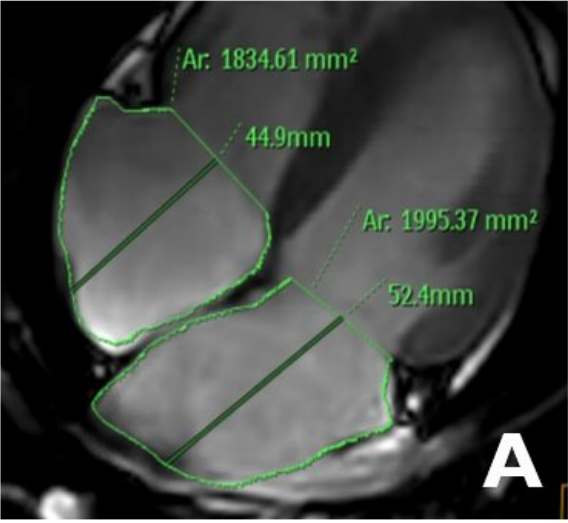


# **Imaging the adolescent heart provides 'normal' reference values for clinical practice**

March 3 2023

---



Cardiac magnetic resonance images used to study distinct aspects of cardiac anatomy and function. (A and B) Atria. (B and C) Ventricles. (E and F) Cardiac tissue characterization. Credit: CNIC

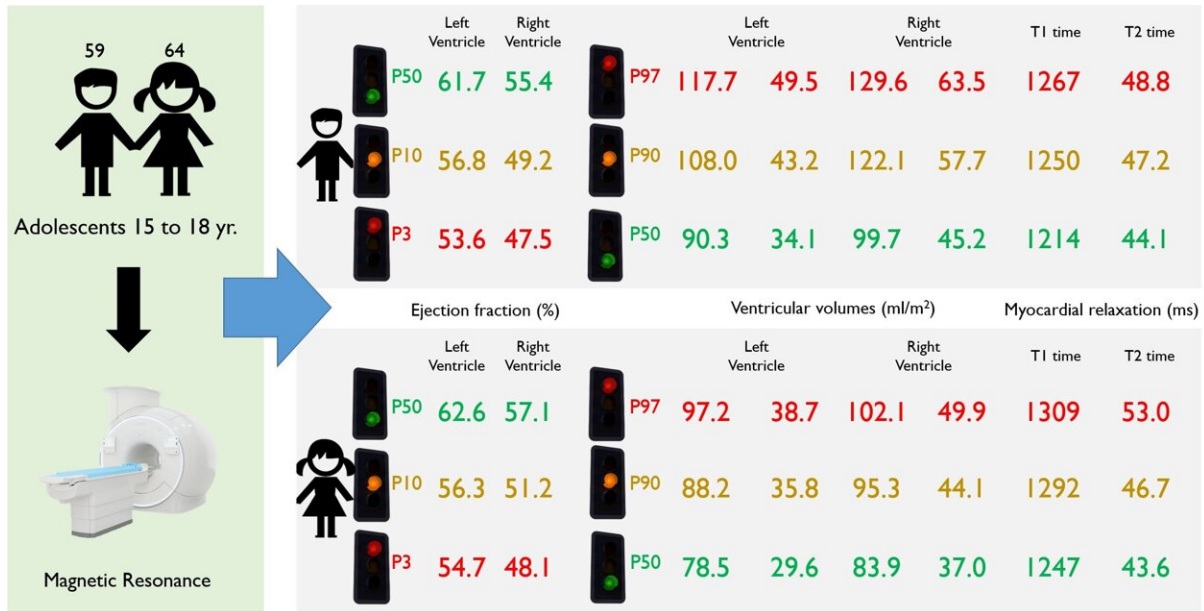
Magnetic resonance imaging (MRI) has allowed scientists at the Centro Nacional de Investigaciones Cardiovasculares (CNIC) to produce an accurate picture of the healthy heart in adolescence. Using this advanced technology, the research team was able to determine reference values for anatomical and functional parameters in the heart during adolescence. This information, published in *eClinicalMedicine*, has direct implications for clinical practice.

"Magnetic resonance imaging has become a very important method for studying the heart because it avoids exposing patients to radiation and provides more information, and with greater precision, than ultrasound, currently the most frequently used cardiac imaging technique," said CNIC General Director Dr. Valentín Fuster, a co-author on the study.

Nevertheless, most published MRI data from adolescent subjects come from patients with congenital heart defects or other heart conditions. As a result, there is a lack of knowledge about the "normal" values of cardiac parameters in the general adolescent population. "These reference values are essential for a proper interpretation of cardiac MRI studies in this population group," said lead study author Dr. Rodrigo Fernández-Jiménez, leader of the Cardiovascular Health and Imaging group at the CNIC and a cardiologist at Hospital Clínico San Carlos.

These reference values are precisely what the CNIC team set out to define. As part of the EnIGMA project (Early ImaginG Markers of unhealthy lifestyles in Adolescents), the team managed, in the middle of

the COVID-19 pandemic, to recruit 123 adolescent participants (64 girls and 59 boys) from seven publicly funded [secondary schools](#) within the Comunidad de Madrid. The schools and adolescents were already signed up to the SI! Program for Secondary Schools, a program dedicated to promoting healthy lifestyle habits that is coordinated by Fundación SHE-la Caixa in partnership with the CNIC and the University of Barcelona.



Study design and outcomes, indicating reference values for cardiac parameters commonly used in clinical practice. P3 and P97 represent extreme values (percentiles 3 and 97). Credit: CNIC

"The response of the participants and their families was incredible," said first author Dr. Carlos Real, a CNIC investigator and a resident cardiologist at Hospital Clínico San Carlos. "Some of the schools are located more than 60 km from the city, and the participants and at least one parent or guardian visited the CNIC's advanced imaging facility on an entirely voluntary basis. Without their willingness to participate the project would not have been possible."

Dr. Borja Ibáñez, CNIC Scientific Director and a co-author on the study, stressed that "the results have direct implications for [clinical practice](#) because they provide a list of reference values for multiple cardiac parameters used in [daily practice](#), including measures of the size and functioning of the heart chambers (atria and ventricles) and cardiac tissue composition."

Dr. Fernández-Jiménez concluded that "with this information, physicians at any center can determine if cardiac MRI data from an adolescent's [heart](#) fall within the normal range for this age group, and prescribe closer follow-up and additional tests if needed."

**More information:** Carlos Real et al, Magnetic resonance imaging reference values for cardiac morphology, function and tissue composition in adolescents, *eClinicalMedicine* (2023). [DOI: 10.1016/j.eclinm.2023.101885](https://doi.org/10.1016/j.eclinm.2023.101885)

Provided by Centro Nacional de Investigaciones Cardiovasculares Carlos III (F.S.P.)

Citation: Imaging the adolescent heart provides 'normal' reference values for clinical practice (2023, March 3) retrieved 13 April 2023 from <https://medicalxpress.com/news/2023-03-imaging-adolescent-heart-values-clinical.html>

<p>This document is subject to copyright. Apart from any fair dealing for the purpose of private study or research, no part may be reproduced without the written permission. The content is provided for information purposes only.</p>
------------------------------------------------------------------------------------------------------------------------------------------------------------------------------------------------------------------------------------------