

# MRI identifies compression fractures before cementing

June 5 2013

---

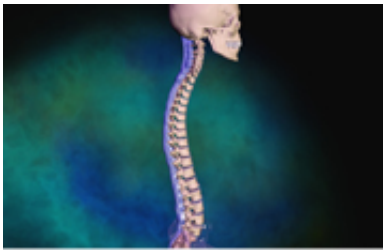


Image courtesy of Blausen Medical

In patients with suspected vertebral compression fractures, the addition of magnetic resonance imaging reduces the rate of misdiagnosis of acute lesions and hidden lesions before percutaneous cement augmentation procedures, according to a study published in the May issue of the *Journal of Spinal Disorders & Techniques*.

(HealthDay)—In patients with suspected vertebral compression fractures, the addition of magnetic resonance imaging (MRI) reduces the rate of misdiagnosis of acute lesions and hidden lesions before percutaneous cement augmentation procedures, according to a study published in the May issue of the *Journal of Spinal Disorders & Techniques*.

Si Young Park, M.D., Ph.D., from the Korea University College of Medicine in Seoul, and colleagues studied 168 patients (at least 50 years of age) who were hospitalized via the emergency room with acute severe back pain and suspected acute osteoporotic vertebral compression

fractures. Patients initially received standard plain radiographs and a computed tomography (CT) of the spine, followed by MRI with short-tau inversion recovery (STIR) sequencing of the spine.

The researchers found that among the 125 patients with a single fracture, as diagnosed by standard radiographs and CT, the concordance rate of diagnosis (the agreement between the level and number of fractures found by standard radiographs and CT compared with MRI) was 77 percent and the discordance rate was 23 percent. Among the 43 patients with multiple fractures of the vertebral body, the discordance rate was 65 percent. The rate of misdiagnosis was significantly higher for the multiple group.

"MRI with STIR sequencing exhibited a multitude of benefits in the exact identification of acute lesions and hidden [lesions](#)," Park and colleagues conclude. "Because of the high rate of [misdiagnosis](#) using standard plain radiographs and CT scans of the spine for osteoporotic [vertebral compression](#) fractures, MRI with STIR sequencing should be considered before cement augmentation procedures."

**More information:** [Abstract](#)  
[Full Text \(subscription or payment may be required\)](#)

[Health News](#) Copyright © 2013 [HealthDay](#). All rights reserved.

Citation: MRI identifies compression fractures before cementing (2013, June 5) retrieved 29 March 2023 from <https://medicalxpress.com/news/2013-06-mri-compression-fractures-cementing.html>

<p>This document is subject to copyright. Apart from any fair dealing for the purpose of private study or research, no part may be reproduced without the written permission. The content is provided for information purposes only.</p>
--