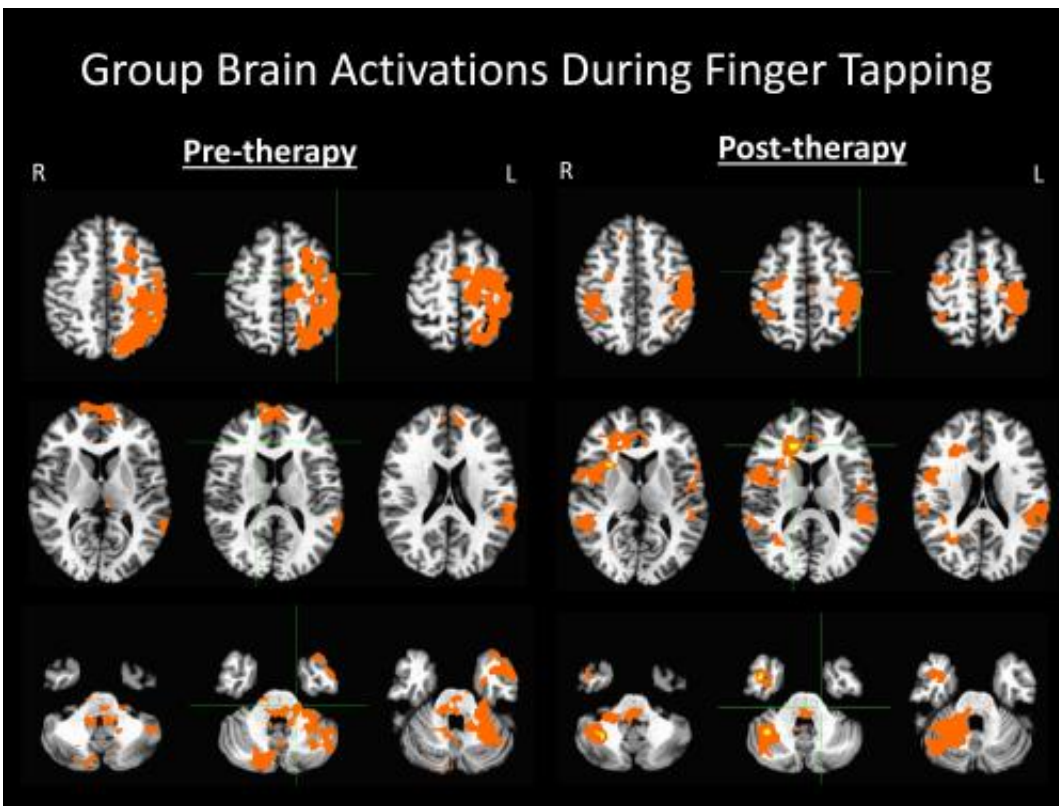


Novel rehabilitation device improves motor skills after stroke

December 2 2013



These are brain activation patterns produced as patients tapped the fingers of their impaired hand before and after four to six weeks of therapy using the BCI-FES device. Credit: Radiological Society of North America

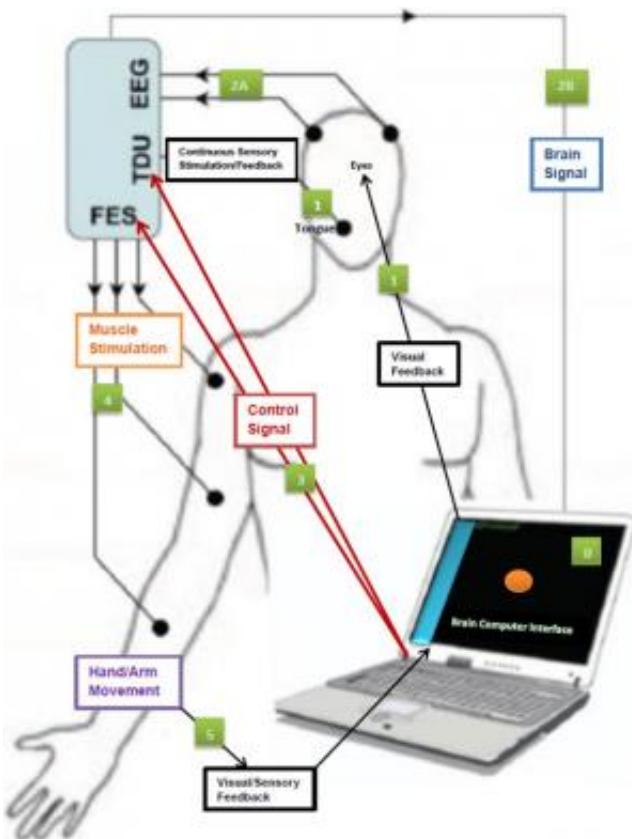
Using a novel stroke rehabilitation device that converts an individual's thoughts to electrical impulses to move upper extremities, stroke patients reported improvements in their motor function and ability to perform

activities of daily living. Results of the study were presented today at the annual meeting of the Radiological Society of North America (RSNA).

"Each year, nearly 800,000 people suffer a new or recurrent stroke in the United States, and 50 percent of those have some degree of upper extremity disability," said Vivek Prabhakaran, M.D., Ph.D., director of functional neuroimaging in radiology at the University of Wisconsin-Madison. "Rehabilitation sessions with our device allow patients to achieve an additional level of recovery and a higher quality of life."

Dr. Prabhakaran, along with co-principal investigator Justin Williams, Ph.D., and a multidisciplinary team, built the new rehabilitation device by pairing a functional electrical stimulation (FES) system, which is currently used to help [stroke patients](#) recover limb function, and a brain control interface (BCI), which provides a direct communication pathway between the brain and this peripheral stimulation device.

In an FES system, electrical currents are used to activate nerves in paralyzed extremities. Using a computer and an electrode cap placed on the head, the new BCI-FES device (called the Closed-Loop Neural Activity-Triggered Stroke Rehabilitation Device) interprets [electrical impulses](#) from the brain and transmits the information to the FES.



This is a schematic representation of the BCI-FES device indicating input and feedback components. Credit: Radiological Society of North America

"FES is a passive technique in that the electrical impulses move the patients' extremities for them," Dr. Prabhakaran said. "When a patient using our device is asked to imagine or attempt to move his or her hand, the BCI translates that brain activity to a signal that triggers the FES. Our system adds an active component to the rehabilitation by linking brain activity to the peripheral stimulation device, which gives the patients direct control over their movement."

The Wisconsin team conducted a small clinical trial of their rehabilitation device, enlisting eight patients with one hand affected by stroke. The patients were also able to serve as a control group by using

their normal, unaffected hand. Patients in the study represented a wide range of stroke severity and amount of time elapsed since the stroke occurred. Despite having received standard rehabilitative care, the patients had varying degrees of residual motor deficits in their upper extremities. Each underwent nine to 15 rehabilitation sessions of two to three hours with the new device over a period of three to six weeks.

The patients also underwent functional magnetic resonance imaging (fMRI) and diffusion tensor imaging (DTI) before, at the mid-point of, at the end of, and one month following the rehabilitation period. fMRI is able to show which areas of the brain are activated while the patient performs a task, and DTI reveals the integrity of fibers within the white matter that connects the brain's functional areas.

Patients who suffered a stroke of moderate severity realized the greatest improvements to [motor function](#) following the rehabilitation sessions. Patients diagnosed with mild and severe strokes reported improved ability to complete activities of daily living following rehabilitation.

Dr. Prabhakaran said the results captured throughout the rehabilitation process—specifically the ratio of hemispheric involvement of motor areas—related well to the behavioral changes observed in patients. A comparison of pre-rehabilitation and post-rehabilitation fMRI results revealed reorganization in the regions of the brain responsible for motor function. DTI results over the course of the rehabilitation period revealed a gradual strengthening of the integrity of the fiber tracts.

"Our hope is that this device not only shortens [rehabilitation](#) time for stroke [patients](#), but also that it brings a higher level of recovery than is achievable with the current standard of care," Dr. Prabhakaran said. "We believe brain imaging will be helpful in both planning and tracking a [stroke](#) patient's therapy, as well as learning more about neuroplastic changes during recovery."

Provided by Radiological Society of North America

Citation: Novel rehabilitation device improves motor skills after stroke (2013, December 2)
retrieved 21 May 2023 from <https://medicalxpress.com/news/2013-12-device-motor-skills.html>

This document is subject to copyright. Apart from any fair dealing for the purpose of private study or research, no part may be reproduced without the written permission. The content is provided for information purposes only.