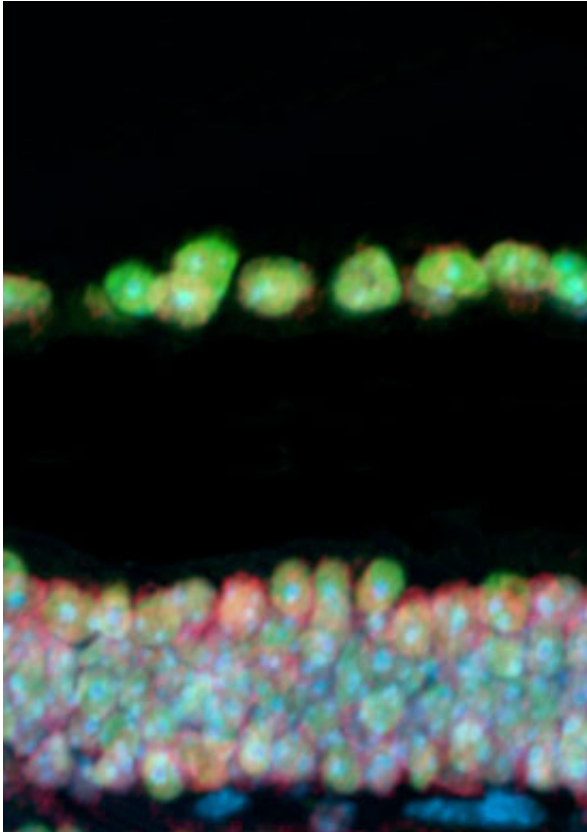


Retinal thinning can be used as an early marker for frontotemporal dementia

25 August 2014



A retina cross-section from a healthy mouse showing TDP-43 staining (green), Ran staining (red), and nuclei (blue). Credit: Dr. Michael Ward

Researchers at the Gladstone Institutes and University of California, San Francisco have shown that a loss of cells in the retina is one of the earliest signs of frontotemporal dementia (FTD) in people with a genetic risk for the disorder—even before any changes appear in their behavior.

Published today in the *Journal of Experimental Medicine*, the researchers, led by Gladstone investigator Li Gan, PhD and UCSF associate professor of neurology Ari Green, MD, studied a group of individuals who had a certain genetic mutation that is known to result in FTD. They

discovered that before any cognitive signs of dementia were present, these individuals showed a significant thinning of the retina compared with people who did not have the gene mutation.

"This finding suggests that the retina acts as a type of 'window to the brain,'" said Dr. Gan. "Retinal degeneration was detectable in mutation carriers prior to the onset of cognitive symptoms, establishing retinal thinning as one of the earliest observable signs of familial FTD. This means that retinal thinning could be an easily measured outcome for clinical trials."

Although it is located in the eye, the retina is made up of neurons with direct connections to the brain. This means that studying the retina is one of the easiest and most accessible ways to examine and track changes in neurons.

Lead author Michael Ward, MD, PhD, a postdoctoral fellow at the Gladstone Institutes and assistant professor of neurology at UCSF, explained, "The retina may be used as a model to study the development of FTD in neurons. If we follow these patients over time, we may be able to correlate a decline in retinal thickness with disease progression. In addition, we may be able to track the effectiveness of a treatment through a simple eye examination."

The researchers also discovered new mechanisms by which cell death occurs in FTD. As with most complex neurological disorders, there are several changes in the brain that contribute to the development of FTD. In the inherited form researched in the current study, this includes a deficiency of the protein progranulin, which is tied to the mislocalization of another crucial protein, TDP-43, from the nucleus of the cell out to the cytoplasm.

However, the relationship between neurodegeneration, progranulin, and TDP-43 was

previously unclear. In follow-up studies using a genetic mouse model of FTD, the scientists were able to investigate this connection for the first time in neurons from the retina. They identified a depletion of TDP-43 from the cell nuclei before any signs of neurodegeneration occurred, signifying that this loss may be a direct cause of the cell death associated with FTD.

TDP-43 levels were shown to be regulated by a third cellular protein called Ran. By increasing expression of Ran, the researchers were able to elevate TDP-43 levels in the nucleus of progranulin-deficient neurons and prevent their death.

"With these findings," said Dr. Gan, "we now not only know that retinal thinning can act as a pre-symptomatic marker of dementia, but we've also gained an understanding into the underlying mechanisms of [frontotemporal dementia](#) that could potentially lead to novel therapeutic targets."

Provided by Gladstone Institutes

APA citation: Retinal thinning can be used as an early marker for frontotemporal dementia (2014, August 25) retrieved 23 June 2022 from <https://medicalxpress.com/news/2014-08-retinal-thinning-early-marker-frontotemporal.html>

This document is subject to copyright. Apart from any fair dealing for the purpose of private study or research, no part may be reproduced without the written permission. The content is provided for information purposes only.