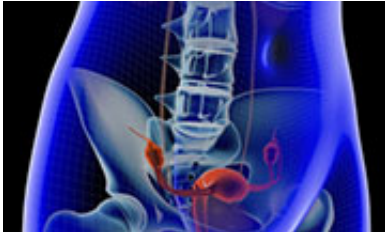


Tattoos can mimic metastasis on PET-CT in cervical cancer

14 June 2015

Copyright © 2015 [HealthDay](#). All rights reserved.



(HealthDay)—For patients with cervical cancer, extensive tattoos could mimic metastasis on positron emission tomography (PET) fused with computed tomography (CT) imaging, according to a case report published online June 5 in *Obstetrics & Gynecology*.

Narine Grove, M.D., from the University of California in Orange, and colleagues describe the case of a 32-year-old woman presenting with clinical stage 1B1 [cervical cancer](#) and extensive tattoos of the lower extremities.

The researchers note that two ileac lymph nodes considered suspicious for metastatic disease were identified in preoperative PET-CT scan with increased fluorine-18-deoxyglucose uptake. Bilateral pigmented lymph nodes were identified at the time of surgical resection; however, histologic examination showed deposition of tattoo ink and no evidence of malignant cells.

"Physicians should be cognizant of the possible effects of tattoos on PET-CT findings while counseling patients and formulating a treatment program," the authors write.

More information: [Full Text \(subscription or payment may be required\)](#)

APA citation: Tattoos can mimic metastasis on PET-CT in cervical cancer (2015, June 14) retrieved 5 November 2022 from <https://medicalxpress.com/news/2015-06-tattoos-mimic-metastasis-pet-ct-cervical.html>

This document is subject to copyright. Apart from any fair dealing for the purpose of private study or research, no part may be reproduced without the written permission. The content is provided for information purposes only.