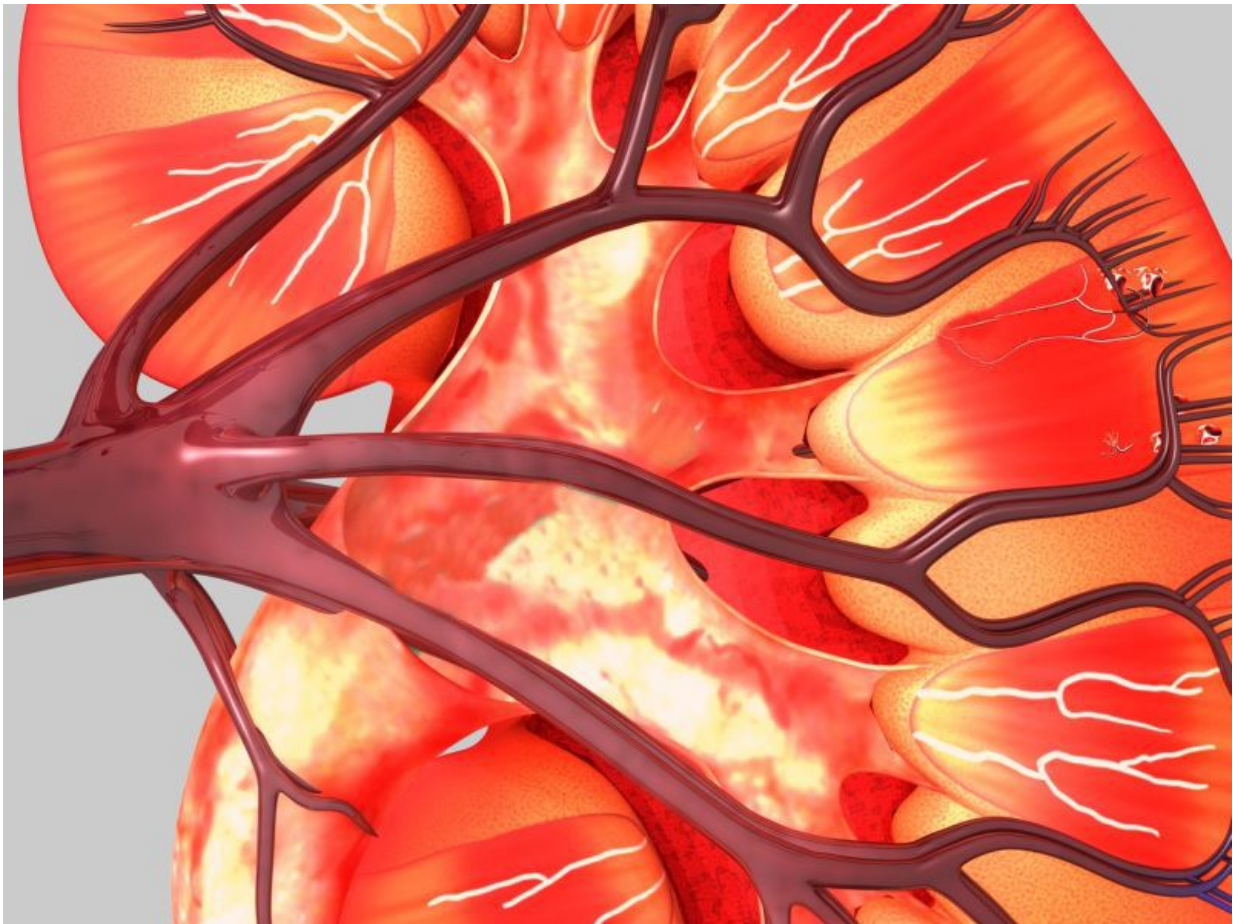


Case report: Ceftriaxone-linked renal toxicity in adult male

March 21 2016



(HealthDay)—A case of ceftriaxone-associated renal toxicity in an adult

has been documented in a case report published online Feb. 23 in the *Journal of Clinical Pharmacy and Therapeutics*.

W. Shen-hua, M.D., from Zhejiang University in Hangzhou, China, and colleagues describe a case of ceftriaxone-associated urolithiasis and post-renal acute [renal failure](#) (PARF) in a 25-year-old male. The patient developed colicky abdominal pain, anuria, and bilateral renal colic during administration of intravenous ceftriaxone. Ceftriaxone administration was discontinued immediately.

The researchers identified elevated serum creatinine, and urinary tract ultrasound revealed bilateral mild hydronephrosis and proximal ureterectasia. Bilateral ureteropyelectasia and contrast medium failed to fill bilateral pelvises and ureters on abdominal enhanced computed tomography. The patient did not respond to pharmacotherapy. Following double J stent insertions by cystoscopy, the symptoms were resolved and [renal function](#) was normalized.

"Overdose [administration](#) of ceftriaxone was related to urolithiasis and PARF in adults. Multidetector-row computed tomography and maximum intensity projections were efficient and effective in identifying ceftriaxone-associated urolithiasis," the authors write. "Treatment should be optimized, including prompt J stent insertions by cystoscopy."

More information: [Abstract](#)
[Full Text \(subscription or payment may be required\)](#)

Copyright © 2016 [HealthDay](#). All rights reserved.

Citation: Case report: Ceftriaxone-linked renal toxicity in adult male (2016, March 21) retrieved 15 February 2023 from <https://medicalxpress.com/news/2016-03-case-ceftriaxone-linked-renal-toxicity-adult.html>

This document is subject to copyright. Apart from any fair dealing for the purpose of private study or research, no part may be reproduced without the written permission. The content is provided for information purposes only.