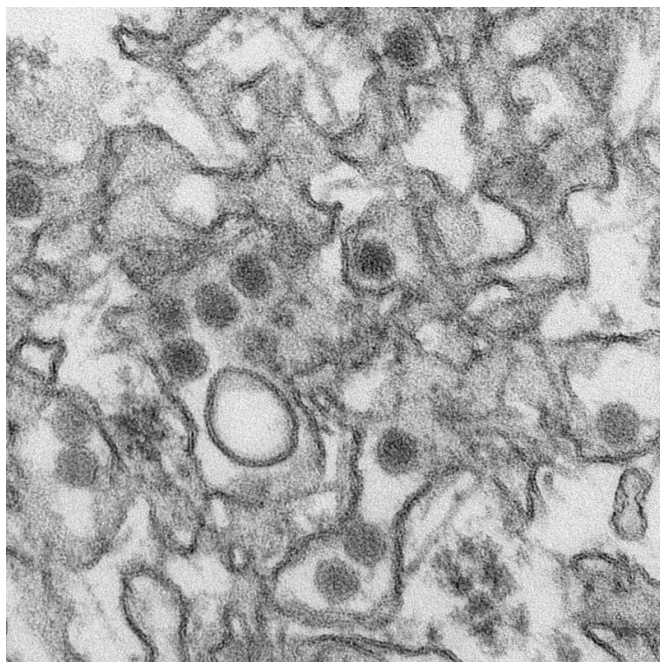


Study identifies risk factors associated with eye abnormalities in infants with presumed Zika virus

26 May 2016



Transmission electron micrograph (TEM) of Zika virus. Credit: Cynthia Goldsmith/Centers for Disease Control and Prevention

In a study published online by *JAMA Ophthalmology*, Rubens Belfort Jr., M.D., Ph.D., of the Federal University of Sao Paulo and Vision Institute, Sao Paulo, Brazil, and colleagues assessed and identified possible risk factors for ophthalmoscopic (an instrument used to visualize the back of the eye) findings in infants born with microcephaly (a birth defect characterized by an abnormally small head) and a presumed clinical diagnosis of Zika virus intrauterine infection.

It is estimated that more than 1 million Brazilians have had the Zika virus (ZIKV) infection since April 2015, reflecting the virus' capacity to cause large-scale outbreaks where the vector is present. After

the Brazilian ZIKV outbreak, an unexpected increase in the number of newborns with microcephaly was identified. An update issued by the Brazilian Ministry of Health released in January 2016 reported 3,174 suspected cases. The Zika [virus](#) has been linked to microcephaly and ophthalmoscopic findings in infants of mothers infected during pregnancy.

For this study, the researchers included 40 infants with microcephaly born in Pernambuco state, Brazil, between May and December 2015. Testing of cerebrospinal fluid for ZIKV was performed in 24 of 40 infants (60 percent). The infants and mothers underwent ocular examinations. The infants were divided into 2 groups, those with and without ophthalmoscopic alterations, for comparison.

Among the 40 infants, the average age was 2.2 months. Of the 24 infants tested, 100 percent had positive results for ZIKV infection: 14 from the group with ophthalmoscopic findings and 10 from the group without ophthalmoscopic findings. The major symptoms reported by mothers in both groups were rash, fever, headache, and joint pain. No mothers reported conjunctivitis or other eye symptoms during pregnancy or presented signs of uveitis (inflammation of a part of the eye) at the time of examination.

Thirty-seven eyes of 22 infants had ophthalmoscopic alterations. Analysis indicated that ocular involvement in infants with presumed ZIKV congenital [infection](#) were more often seen in infants with smaller cephalic (head) diameter at birth, and in [infants](#) whose [mothers](#) reported symptoms during the first trimester.

More information: *AMA Ophthalmol.* Published online May 26, 2016. [DOI: 10.1001/jamaophthalmol.2016.1784](#)

Provided by The JAMA Network Journals

APA citation: Study identifies risk factors associated with eye abnormalities in infants with presumed Zika virus (2016, May 26) retrieved 31 May 2021 from <https://medicalxpress.com/news/2016-05-factors-eye-abnormalities-infants-presumed.html>

This document is subject to copyright. Apart from any fair dealing for the purpose of private study or research, no part may be reproduced without the written permission. The content is provided for information purposes only.