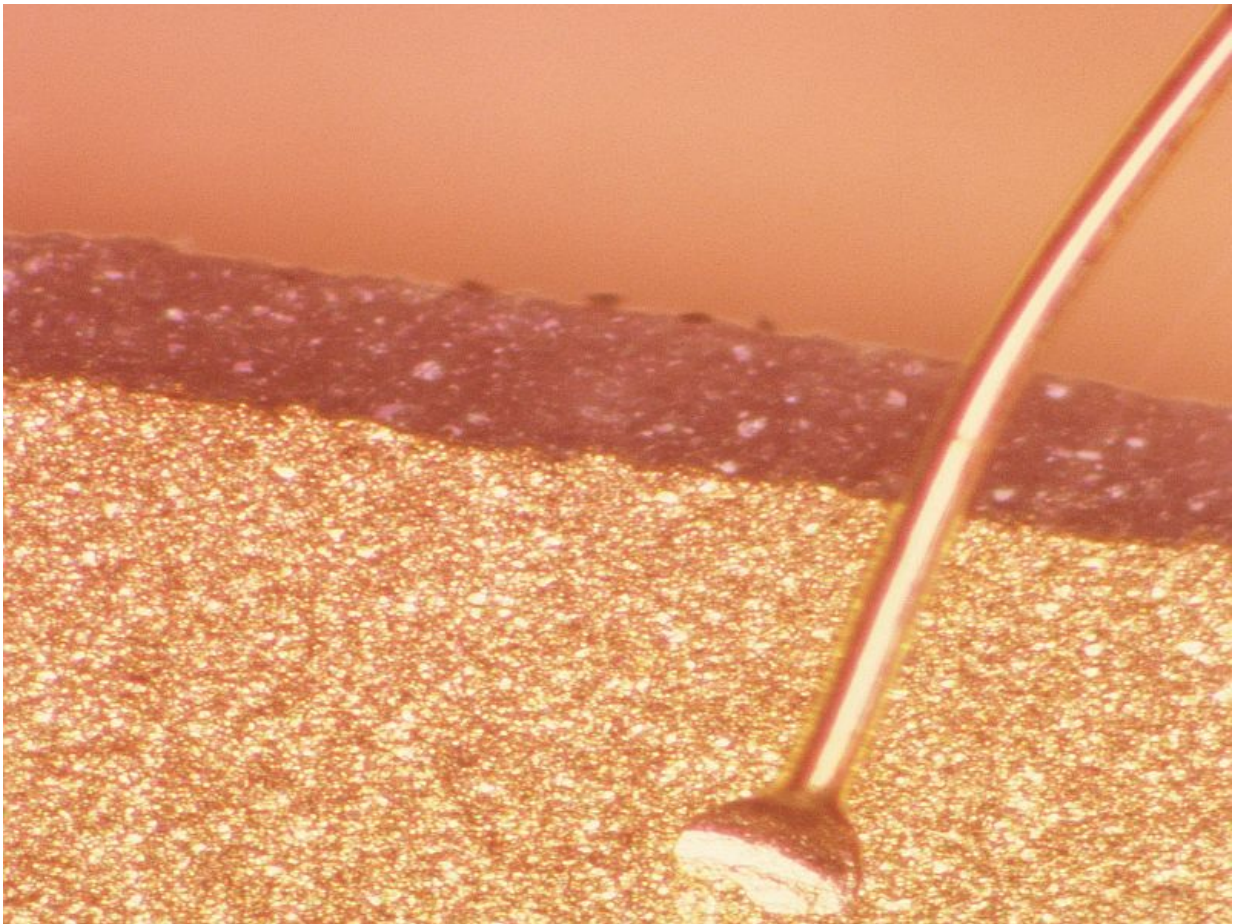


Early, single non-ablative fractional laser Tx aids scarring

August 22 2017



(HealthDay)—Early, single non-ablative fractional laser (NAFL)

exposure can offer improvement in clinical scar appearance, according to a study published online Aug. 16 in *Lasers in Surgery and Medicine*.

Katrine E. Karmisholt, M.D., from Bispebjerg University Hospital in Copenhagen, Denmark, and colleagues conducted a randomized intra-individual trial with erbium glass 1,540 nm NAFL versus no laser treatment on 16 individuals receiving 10 standardized full thickness punch-biopsy wounds. One day before, immediately after, or two weeks after wounding, a single NAFL [exposure](#) was applied to test wounds.

The researchers found that, compared with untreated controls, application of NAFL treatment one day before, immediately after, or two weeks after wounding had the potential to offer subtle, but detectable, improvement in clinical [scar](#) appearance. Compared with untreated controls, NAFL exposure one day before wounding induced improvement (Patient Observer Scar Assessment Scale [POSAS] total, median of 15 versus control median of 16; $P = 0.03$; visual analogue scale, median of 4.1 versus control median of 5.5; $P = 0.03$; medium fluence), as did NAFL exposure immediately and two weeks after wounding (POSAS total: $P \leq 0.05$, low fluence). NAFL-treated and [control](#) scars did not differ significantly in dyschromia. Subtle changes toward more mature interwoven bundles of collagen were seen in NAFL-treated scars versus controls.

"This study indicates that a single NAFL treatment at low to medium fluence performed one day prior, or in the early phases of wound healing, may have the potential to optimize scar formation in full thickness [wounds](#)," the authors write.

More information: [Abstract](#)
[Full Text \(subscription or payment may be required\)](#)

Copyright © 2017 [HealthDay](#). All rights reserved.

Citation: Early, single non-ablative fractional laser Tx aids scarring (2017, August 22) retrieved 24 November 2023 from <https://medicalxpress.com/news/2017-08-early-non-ablative-fractional-laser-tx.html>

This document is subject to copyright. Apart from any fair dealing for the purpose of private study or research, no part may be reproduced without the written permission. The content is provided for information purposes only.