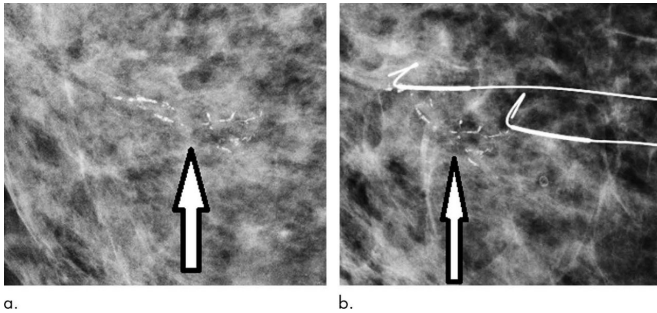


Digital mammography increases breast cancer detection

11 December 2018



Routine screening mammograms from a 73-year-old woman show (a) 25-mm new casting calcifications representing ductal carcinoma in situ (DCIS) (arrow) in medial right breast. (b) Patient was treated with surgical excision guided by bracketed wires. Histologic examination showed high-nuclear-grade DCIS. Credit: Radiological Society of North America

The shift from film to digital mammography increased the detection of breast cancer by 14 percent overall in the United Kingdom without increasing the recall rate, according to a major new study appearing in the journal *Radiology*.

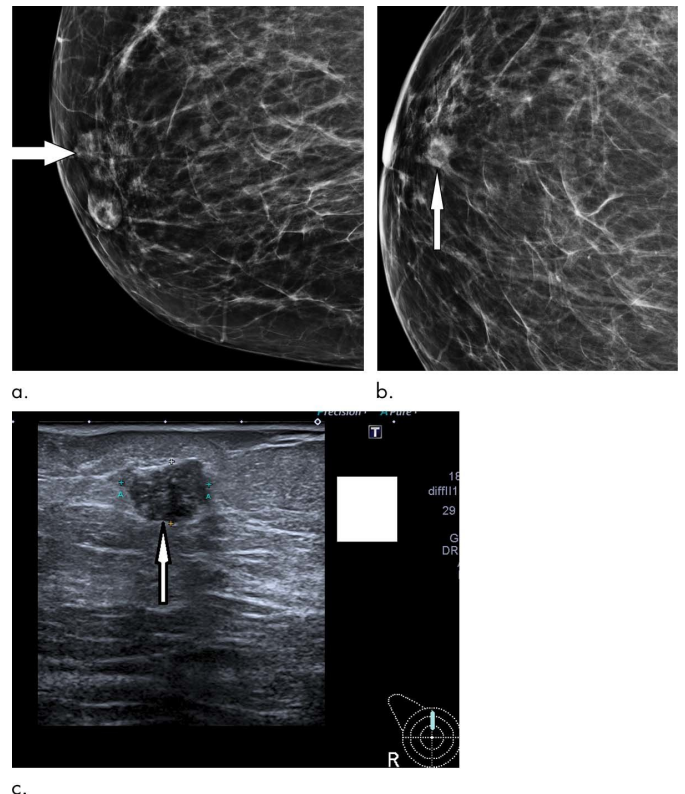
Digital mammography was introduced into clinical use more than 15 years ago and has been widely adopted due to the numerous advantages it has over its predecessor, screen film mammography.

"Image quality with [digital mammography](#) is improved over that of screen film mammography," said radiologist and study coauthor Rosalind M. Given-Wilson, M.B.B.S., from St. Georges University Hospitals NHS Foundation Trust in London. "In particular, digital mammography provides the ability to visualize calcifications and see through denser tissue, and it allows the reader to adjust the image."

Dr. Given-Wilson and colleagues assessed digital mammography's impact on [cancer](#) detection using

data from the 80 facilities of the English National Health Service Breast Cancer Screening Program. The huge trove of data combined with estimates of digital mammography usage enabled the researchers to measure the effect of digital mammography in 11.3 million [screening](#) exams in women between the ages of 45 and 70.

The overall [cancer detection](#) rate was 14 percent greater with digital mammography, with substantially higher detection of grade 1 and grade 2 invasive cancers—early-stage cancers that could advance to life-threatening disease if not detected and treated early enough.



Routine screening mammogram in a 67-year-old woman shows subtle 12-mm asymmetric density with ill-defined margins representing small grade 3 cancer (arrow) on (a) lateral oblique view and (b) cranio-caudal view; it is

difficult to see even on digital mammogram in a nondense breast. Subsequent clinical examination was normal. (c) US confirmed 12-mm irregular hypoechoic mass (arrow). Patient underwent wire-guided surgical excision and sentinel node biopsy. Final histologic examination showed 14-mm grade 3 invasive ductal carcinoma, which was node negative. Credit: Radiological Society of North America

They are also studying the relationship between grade 3 cancers and subsequent interval cancers, or cancers that appear between screenings.

Provided by Radiological Society of North America

At first screening exams for women aged 45 to 52, digital mammography increased the overall detection rate by 19 percent. Importantly, the higher sensitivity of digital mammography did not increase the recall rate—the rate at which women are called back for additional screening based on suspicious results.

"This improvement happened in the absence of other changes in the English screening program, such as a change in recall rate or introduction of computer-aided detection, so we can be clear that the increased rate of detection is due to the change in technology," Dr. Given-Wilson said.

Digital mammography increased the detection of some types of cancers more than others. For instance, digital mammography significantly increased the detection of ductal carcinoma in situ, or DCIS, an early-stage cancer confined to the milk ducts of the breast, at both first screens and subsequent screens.

"These results confirm that digital mammography is superior to screen film mammography in finding invasive cancers and DCIS," Dr. Given-Wilson said. "Women are more likely to have a cancer detected with a digital mammogram."

While digital mammography improved detection of grade 1 and 2 cancers, the researchers found no improvement in the detection of grade 3 invasive cancers. Grade 3 cancers are faster-growing and more likely to spread than grade 1 and 2 cancers.

The [researchers](#) are looking at the radiological features of grade 3 cancers on digital [mammography](#) to see if optimizing the image for these lesions, which are often nonspecific and ill-defined soft tissue densities, can aid detection.

APA citation: Digital mammography increases breast cancer detection (2018, December 11) retrieved 5 October 2022 from <https://medicalxpress.com/news/2018-12-digital-mammography-breast-cancer.html>

This document is subject to copyright. Apart from any fair dealing for the purpose of private study or research, no part may be reproduced without the written permission. The content is provided for information purposes only.